Nervous System

Lab 05 – Special Senses

Models:

- Eye models
- Ear models

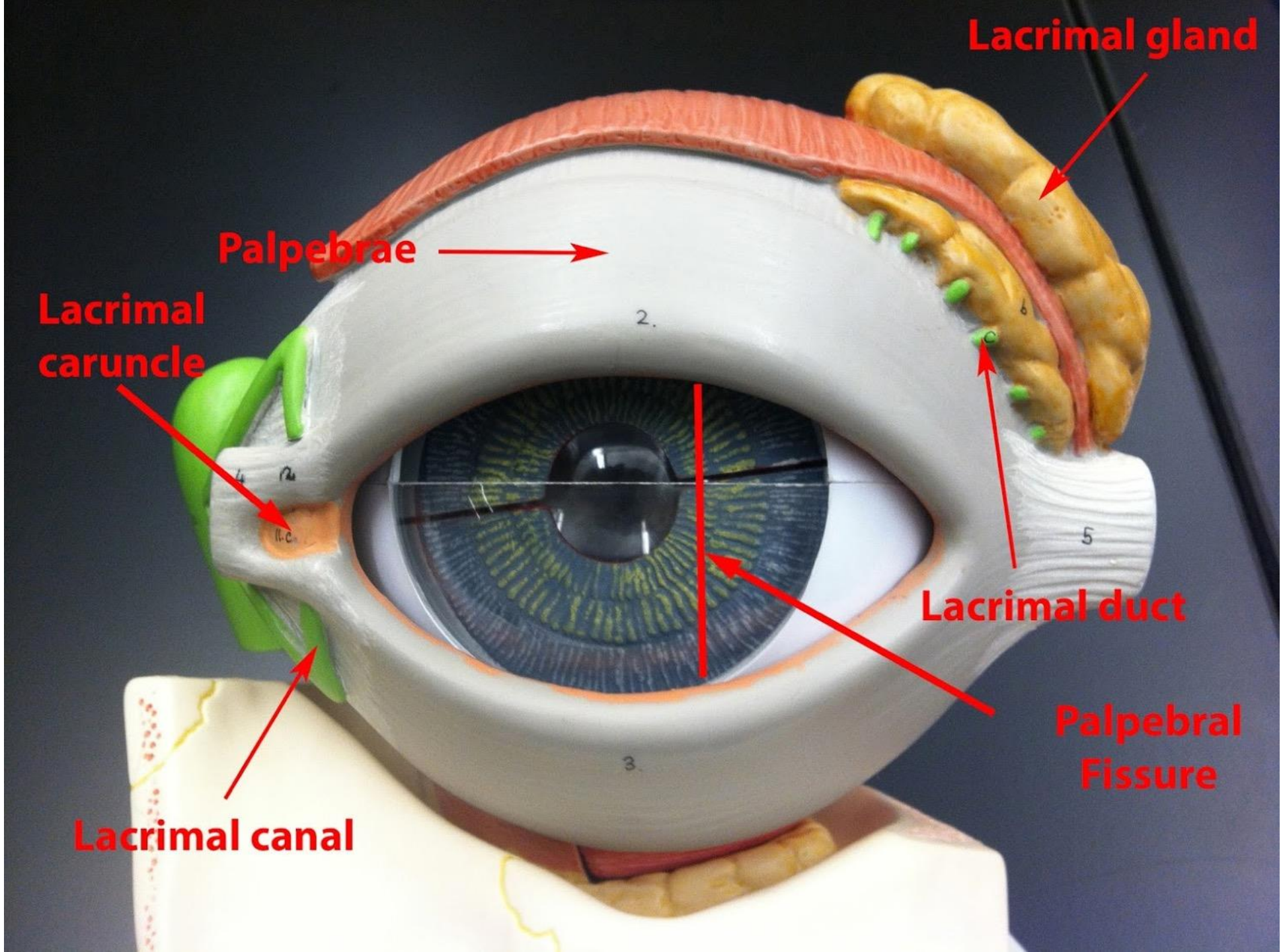
Lacrimal gland
Palpebrae
Lacrimal caruncle
Lacrimal duct
Palpebral Fissure
Lacrimal canal


Cornea
Extrinsic
Eye
Muscles
Optic
Nerve
Sclera


Choroid
Iris
Pupil

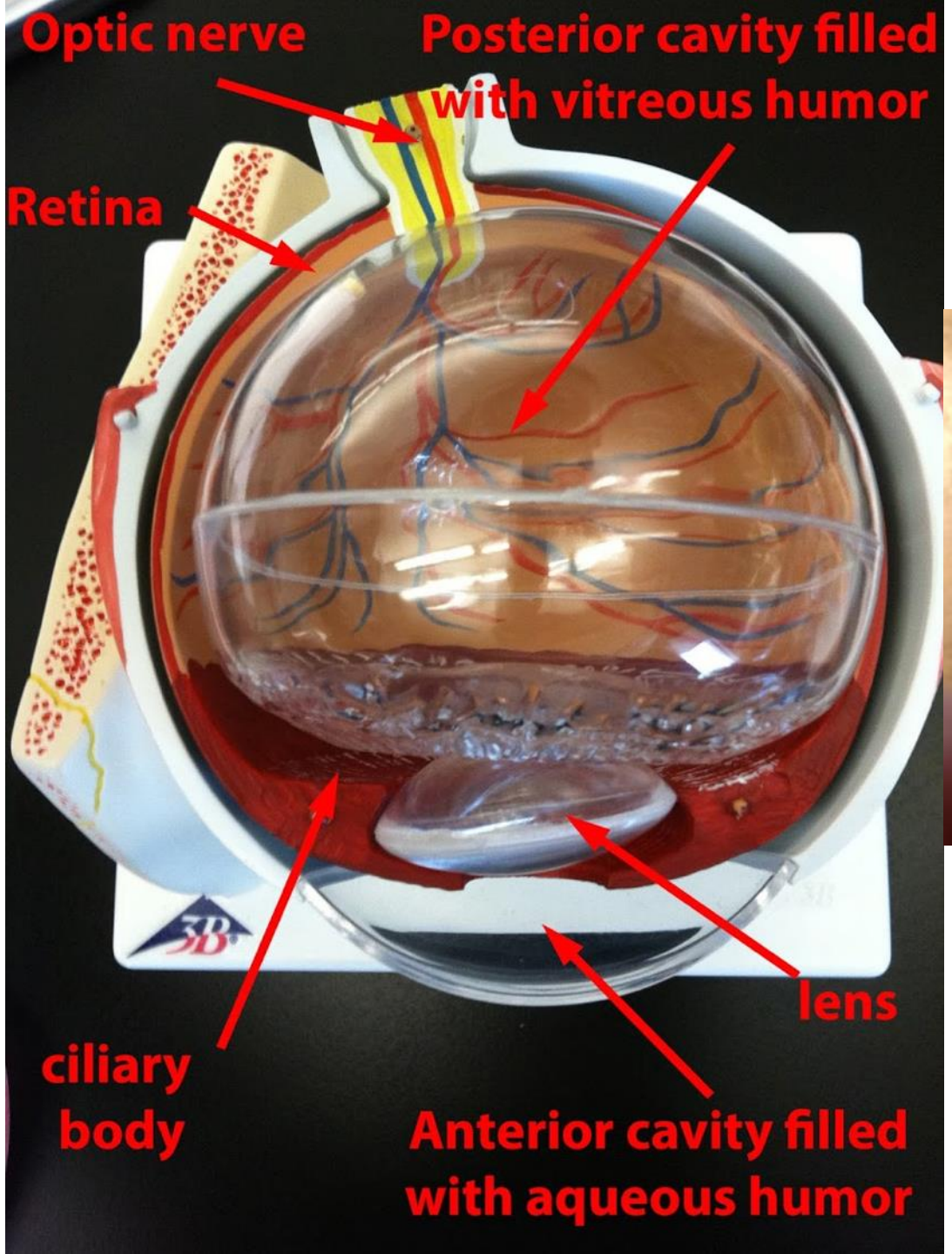
Optic nerve
Posterior cavity filled with vitreous humor
Retina
lens
ciliary body
Anterior cavity filled with aqueous humor

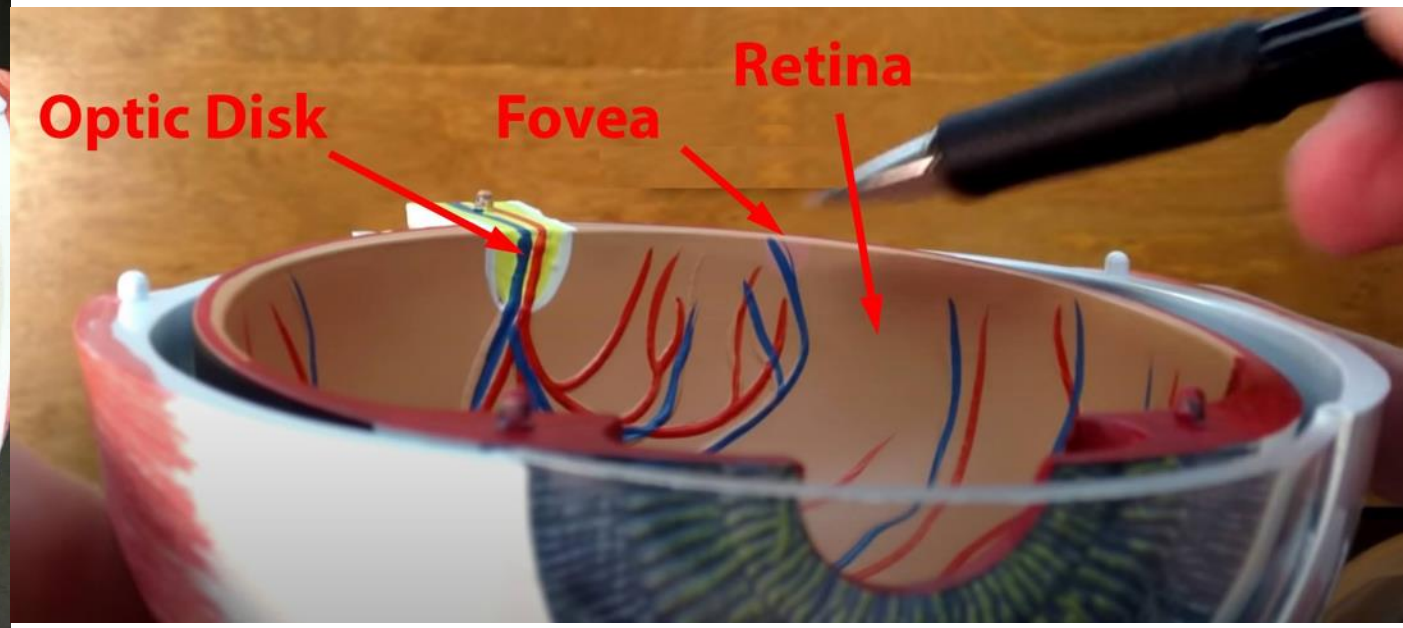
Optic Disk
Fovea
Retina

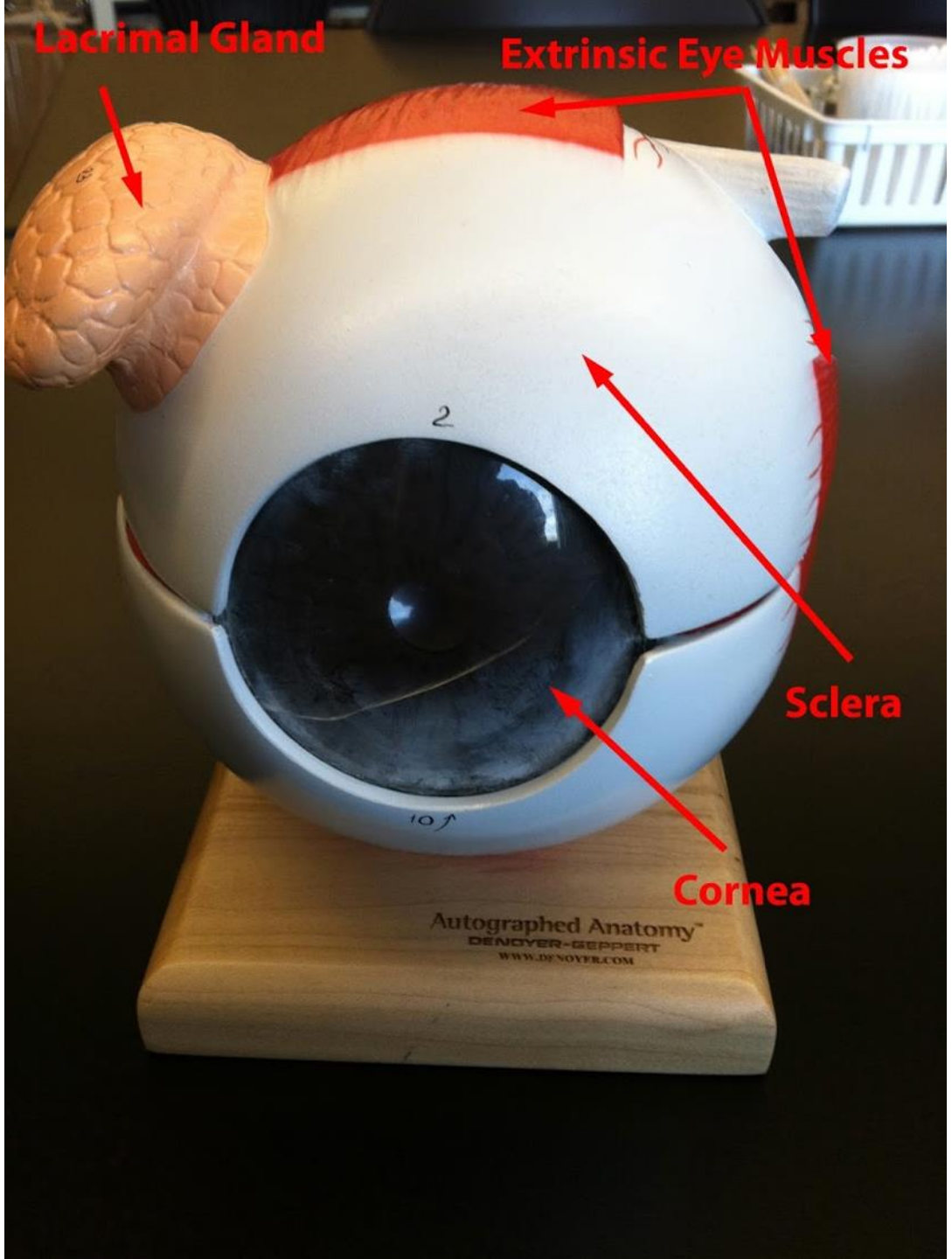
Lacrimal Gland
Extrinsic Eye Muscles
Sclera
Cornea
Autographed Anatomy™
DENOYER-GEPPERT
WWW.DENOYER.COM


Posterior cavity with
Vitreous humor
lens
Anterior cavity with
Aqueous humor

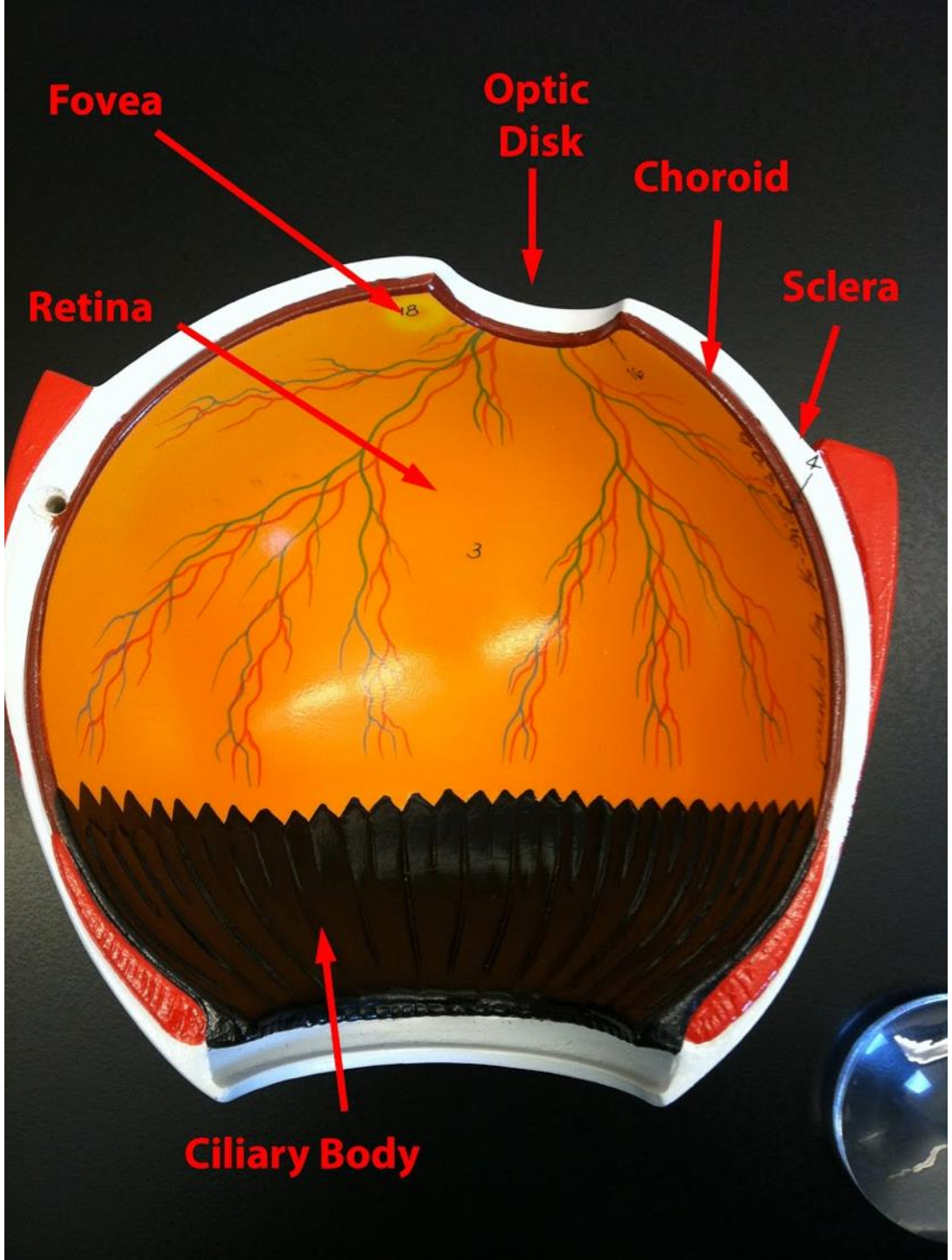
Fovea
Optic Disk
Choroid
Sclera
Retina
Ciliary Body

External Ear

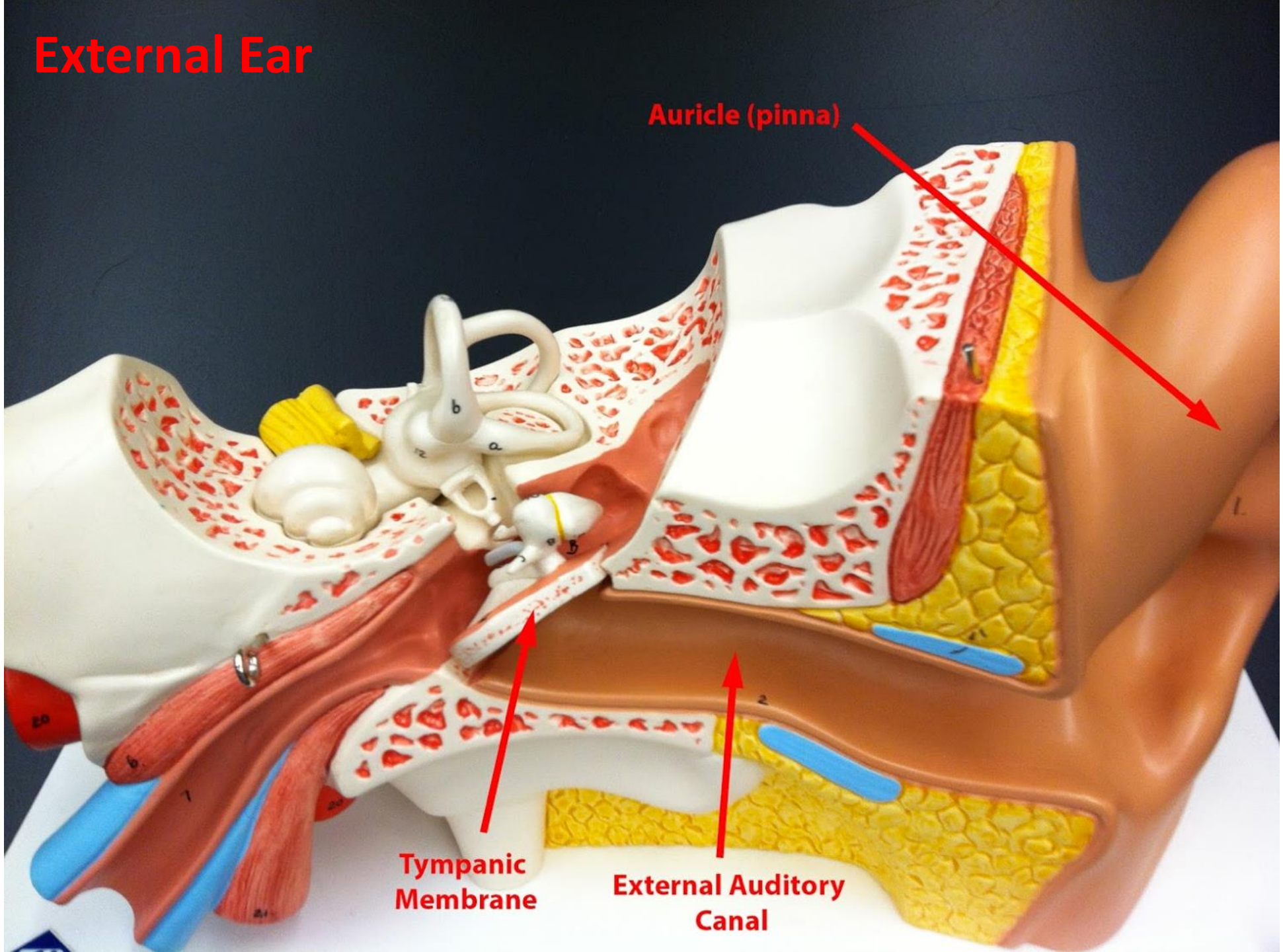

Middle Ear

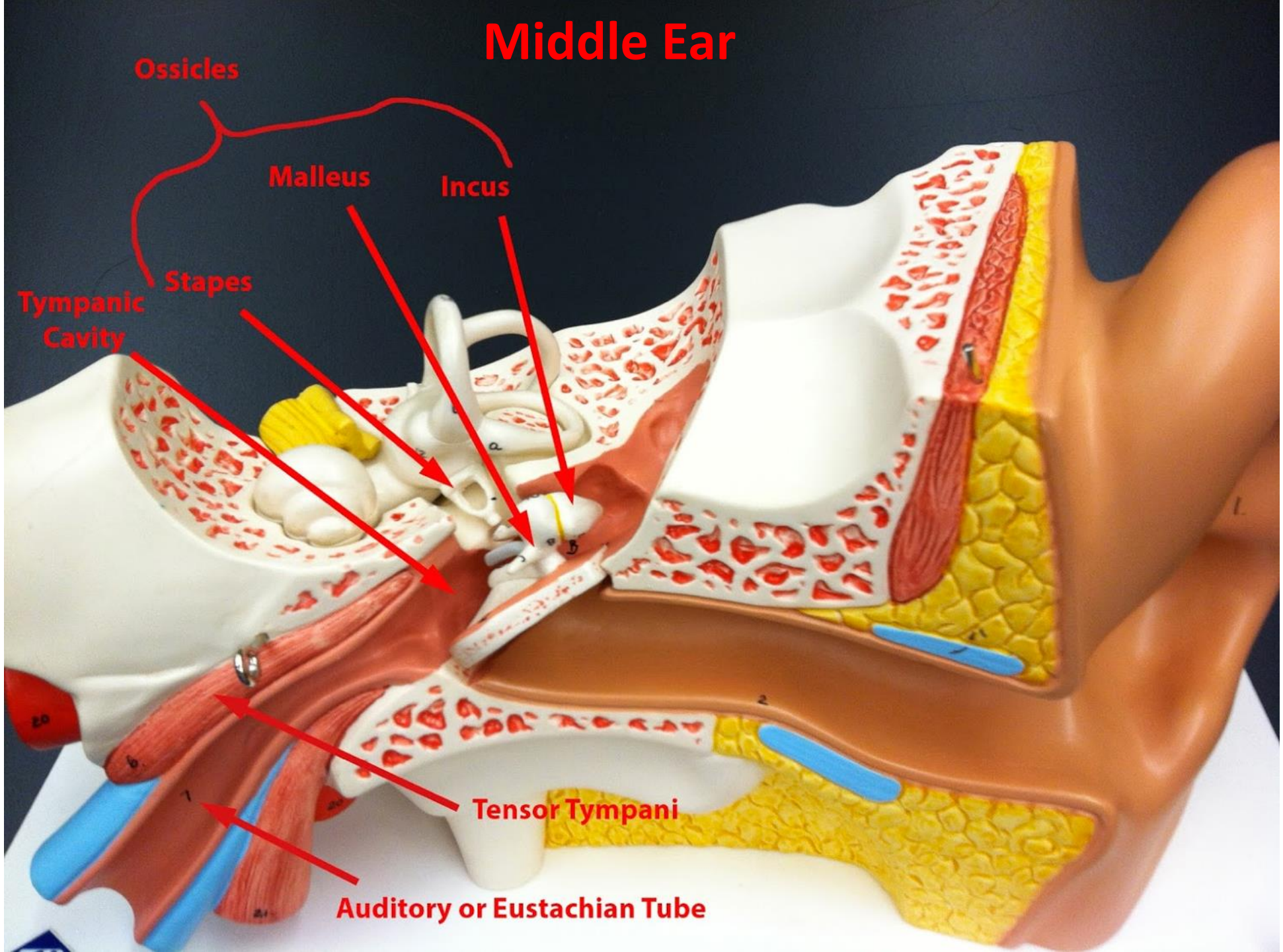
Ossicles
Malleus
Incus
Stapes
Tympanic Cavity
Tensor Tympani
Auditory or Eustachian Tube

Inner Ear

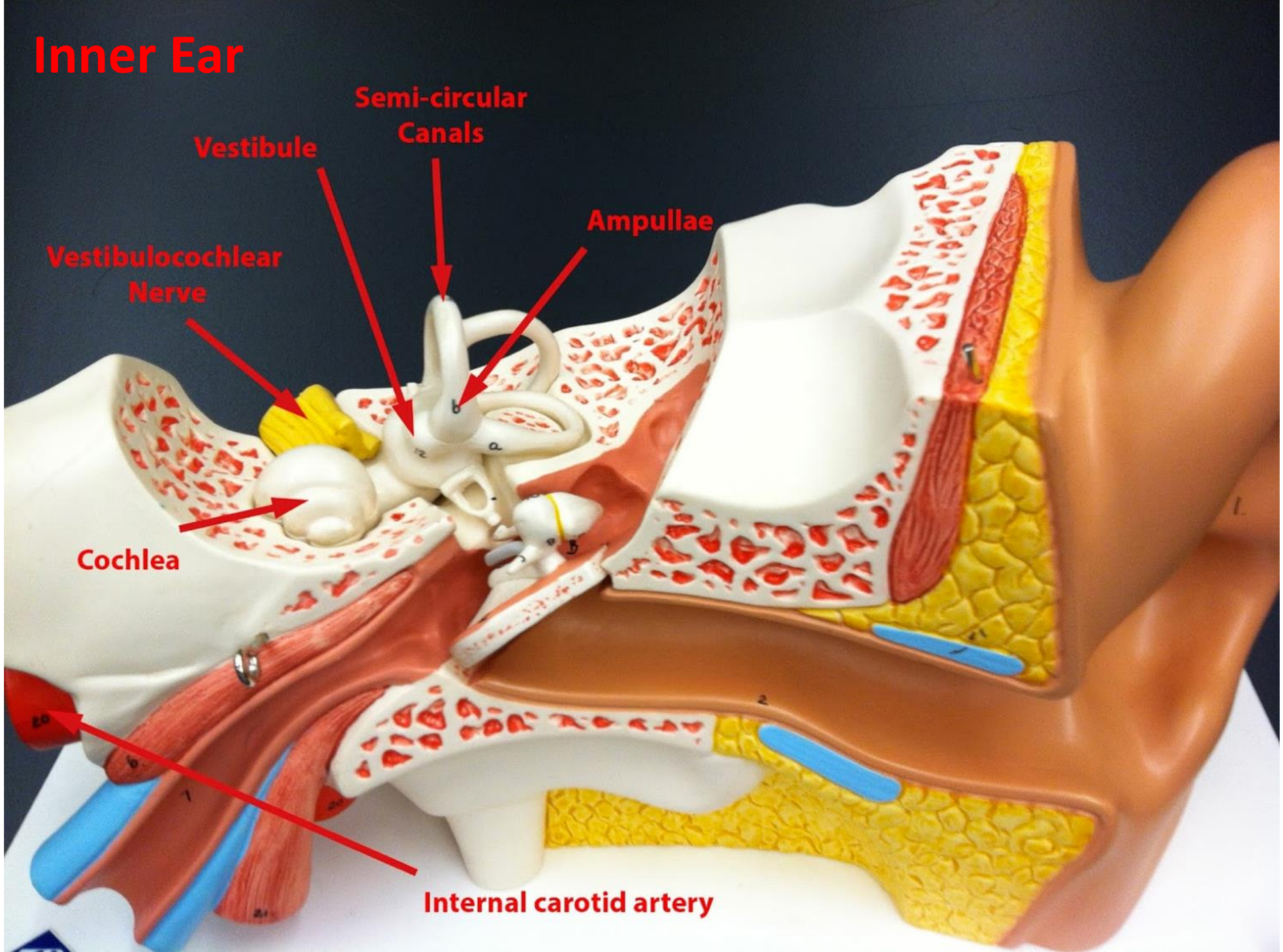
Semi-circular Canals
Vestibule
Ampullae
Vestibulocochlear Nerve
Cochlea
Internal carotid artery